

Acute Osteomyelitis Clinical Practice Guideline

Version: 1

This is a CONTROLLED document for internal use only, valid only if accessed from the Policies and Procedures site.

1.0 Introduction

Acute osteomyelitis (OM) is most often a consequence of hematogenous spread of bacteria from the skin or mucosal surfaces. The most common causative pathogens in otherwise healthy children are *Staphylococcus aureus* and *Kingella kingae*, the latter primarily impacting children 6 months to 4 years of age. Other pathogens include *Streptococcus pneumoniae* and *Streptococcus pyogenes*. While OM can occur in any bone, it is more common in the metaphysis of long tubular bones. The predominant symptom is pain, with children presenting with pseudoparalysis (decreased movement) of the affected limb or limping. Fever may also accompany OM but is not necessary for diagnosis.

The gold standard for diagnosis of OM is pathological assessment of a bone specimen. However, in practice this test is invasive and usually not performed. Magnetic resonance imaging (MRI) is a sensitive non-invasive technique often used to confirm the diagnosis of OM. Laboratory markers, such as white blood cell (WBC) count and C-reactive protein (CRP) can be used in conjunction with clinical features and imaging to support the diagnosis.

All patients with OM require admission to hospital for IV antibiotics and evaluation by a multidisciplinary team, usually consisting of Paediatric Medicine, Infectious Diseases and Orthopaedics. Patients with uncomplicated OM are usually started on IV cefazolin, which provides good coverage for methicillin susceptible *S. aureus* and *K. kingae*. In children older than 4 years of age where *K. kingae* coverage is less important, cloxacillin or cefazolin are reasonable options for empiric therapy. Once the child's clinical status has improved and inflammatory markers are improving, children are transitioned to oral antibiotics to complete the treatment course.

The purpose of this Clinical Practice Guideline is to standardize care for patients with acute osteomyelitis, facilitate collaboration between Paediatric Medicine, Infectious Diseases and Orthopaedics, and improve outcomes.

2.0 Definitions

- Acute osteomyelitis: Infection of the bone with symptom duration < 2 weeks.
- Subacute osteomyelitis: Infection of the bone with symptom duration > 2 weeks
- Chronic osteomyelitis: Infection of the bone with symptom duration > 1 month.

©The Hospital for Sick Children ("SickKids"). All Rights Reserved. This document was developed solely for use at SickKids. SickKids accepts no responsibility for use of this material by any person or organization not associated with SickKids. A printed copy of this document may not reflect the current, electronic version on the SickKids Intranet. Use of this document in any setting must be subject to the professional judgment of the user. No part of the document should be used for publication without prior written consent of SickKids.

- Septic arthritis: Infection of the joint synovial fluid.

Target Users

The target users of this Clinical Practice Guideline include, but are not limited to:

- Paediatric Medicine providers
- Infectious Diseases providers
- Orthopaedic Surgery providers
- Plastic Surgery providers
- Emergency Medicine providers
- Pharmacists
- Radiology and Image Guided Therapy

Target Population

Inclusion criteria: This inpatient management pathway is primarily intended for use in clinically stable children ≥ 3 months of age with a diagnosis or suspected diagnosis of acute OM. For initial management in the ED, see: ED Pathway for Suspected Acute Osteoarticular Infection

Exclusion criteria: The Clinical Practice Guideline is not intended for use in patients who:

- Are < 3 months of age
- Have sickle cell disease (inclusive of any genotype)
- Are immunocompromised (including asplenic patients)
- Are hemodynamically unstable (e.g., septic shock)
- Have chronic or subacute osteomyelitis
- Have a diagnosis of osteomyelitis of the frontal bone (Pott puffy tumor), spine, jaw, or skull
- Have a diagnosis of acute multifocal osteomyelitis or recurrent osteomyelitis
- Have a diagnosis of osteomyelitis involving the digits or other bones of the hand. These infections are not usually acute, and most often present with pain and swelling without fever. Plastic surgery should be engaged for hand infections

3.0 Guideline

Osteomyelitis Pathway

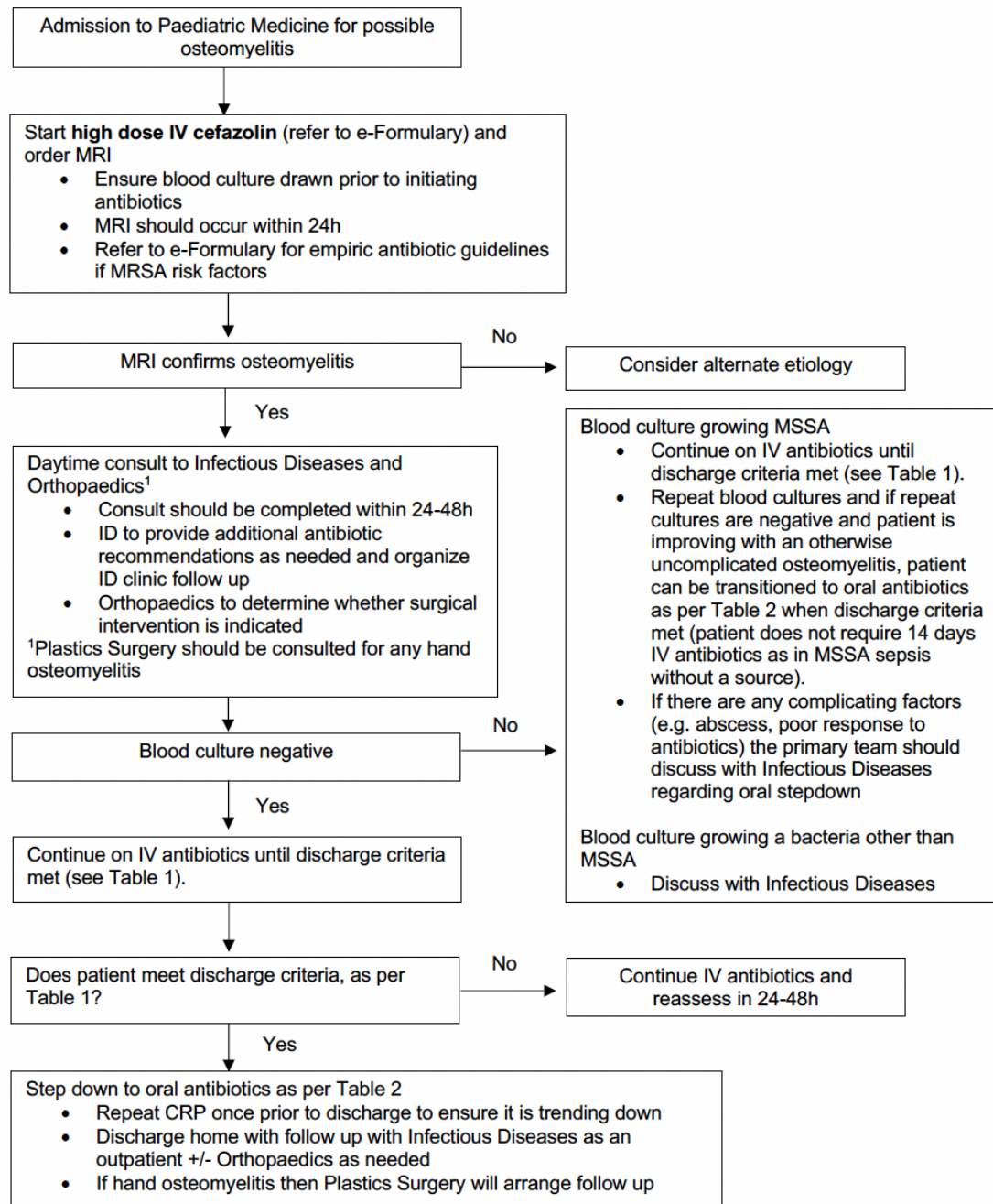


Table 1: Discharge Criteria

If discharge criteria is met, switch to oral antibiotics as per Table 2

- Clinical improvement
 - Afebrile for > 24hrs
 - Significant reduction in pain and local signs of inflammation
 - Improved musculoskeletal function (e.g., improved range of motion of affected area; with lower extremity there should be an ability to weight bear, with upper extremity infection there should be only mild pain with routine use) ^{1, 2}
- AND down trending CRP

1. Clinical Practice Guideline by the Pediatric Infectious Diseases Society and the Infectious Diseases Society of America: 2021 Guideline on Diagnosis and Management of Acute Hematogenous Osteomyelitis in Pediatrics 2021
2. CPS Position Statement: Diagnosis and management of acute osteoarticular infections in children

Table 2: Transition to Oral Antibiotics

- If pathogen was obtained from culture, then oral conversion should be based on susceptibilities
- If no pathogen was obtained, then use the following for guidance:

Empiric IV Antibiotic Used:	Step-Down Oral Antibiotic:	Total Duration of Antibiotic Therapy (IV and PO);
Cefazolin	Cephalixin <ul style="list-style-type: none"> • 50 mg/kg/dose PO TID • ≥ 40kg: 1500 mg PO qam, 1000 mg PO mid-day, and 1500 mg PO qhs • Dose Limit: 4g/day 	<ul style="list-style-type: none"> • For uncomplicated cases of OM, duration of antimicrobial therapy is 3 to 4 weeks • For unusual locations, including frontal bone, spine, jaw, or skull osteomyelitis, or complicated cases, consult Infectious Disease for options
Vancomycin	Consult Infectious Disease for options	

4.0 Related Documents

- <https://cps.ca/en/documents/position/osteoarticular-infections-in-children>
- <https://www.idsociety.org/practice-guideline/bone-and-joint-infections---osteomyelitis/>

5.0 References

1. Le Saux N. (2018). Diagnosis and management of acute osteoarticular infections in children. *Paediatrics & child health*, 23(5), 336–343. <https://doi.org/10.1093/pch/pxy049>
2. Woods, C. R., Bradley, J. S., Chatterjee, A., Copley, L. A., Robinson, J., Kronman, M. P., Arrieta, A., Fowler, S. L., Harrison, C., Carrillo-Marquez, M. A., Arnold, S. R., Eppes, S. C., Stadler, L. P., Allen, C. H., Mazur, L. J., Creech, C. B., Shah, S. S., Zaoutis, T., Feldman, D. S., & Laverne, V. (2021). Clinical Practice Guideline by the Pediatric Infectious Diseases Society and the Infectious

©The Hospital for Sick Children ("SickKids"). All Rights Reserved. This document was developed solely for use at SickKids. SickKids accepts no responsibility for use of this material by any person or organization not associated with SickKids. A printed copy of this document may not reflect the current, electronic version on the SickKids Intranet. Use of this document in any setting must be subject to the professional judgment of the user. No part of the document should be used for publication without prior written consent of SickKids.

Diseases Society of America: 2021 Guideline on Diagnosis and Management of Acute Hematogenous Osteomyelitis in Pediatrics. Journal of the Pediatric Infectious Diseases Society, 10(8), 801–844. <https://doi.org/10.1093/jpids/piab027>