

Acute Splenic Sequestration: Guidelines for Management in Children with Sickle Cell Disease

Version: 3

This is a CONTROLLED document for internal use only, valid only if accessed from the Policies and Procedures site.

1.0 Background

By 4–5 months of age, splenomegaly develops in some infants with sickle cell disease, and by 12 months of age a palpable spleen is noted in nearly half. Although enlarged, the spleen does not properly perform its filtration function. However, its reservoir function is overactive: sequestration of large quantities of blood (often half or more of a child's blood volume) can occur rapidly. This complication, termed acute splenic sequestration, is characterized by pooling of large quantities of sickled RBCs in the splenic red pulp, sudden enlargement of the spleen (within hours), and a precipitous decline in haemoglobin (Hb) and platelets, and an increase in reticulocytes.

Presentation is often (60%) associated with episodes of fever, suggesting an underlying viral etiology. Most commonly occurs in infants and young children between 6 months and 5 years of age with sickle cell anaemia. It may also occur in older patients with any sickle cell phenotype with or without chronic splenomegaly. Often there is no obvious triggering event.

2.0 Clinical/Laboratory Features

A child with an acute splenic sequestration presents with symptoms of:

- acute anaemia (pallor, tachycardia, frank cardiovascular collapse);
- splenomegaly/abdominal pain (pain in the left upper quadrant); and
- evidence of an active bone marrow response (increased reticulocytes) plus or minus thrombocytopenia.

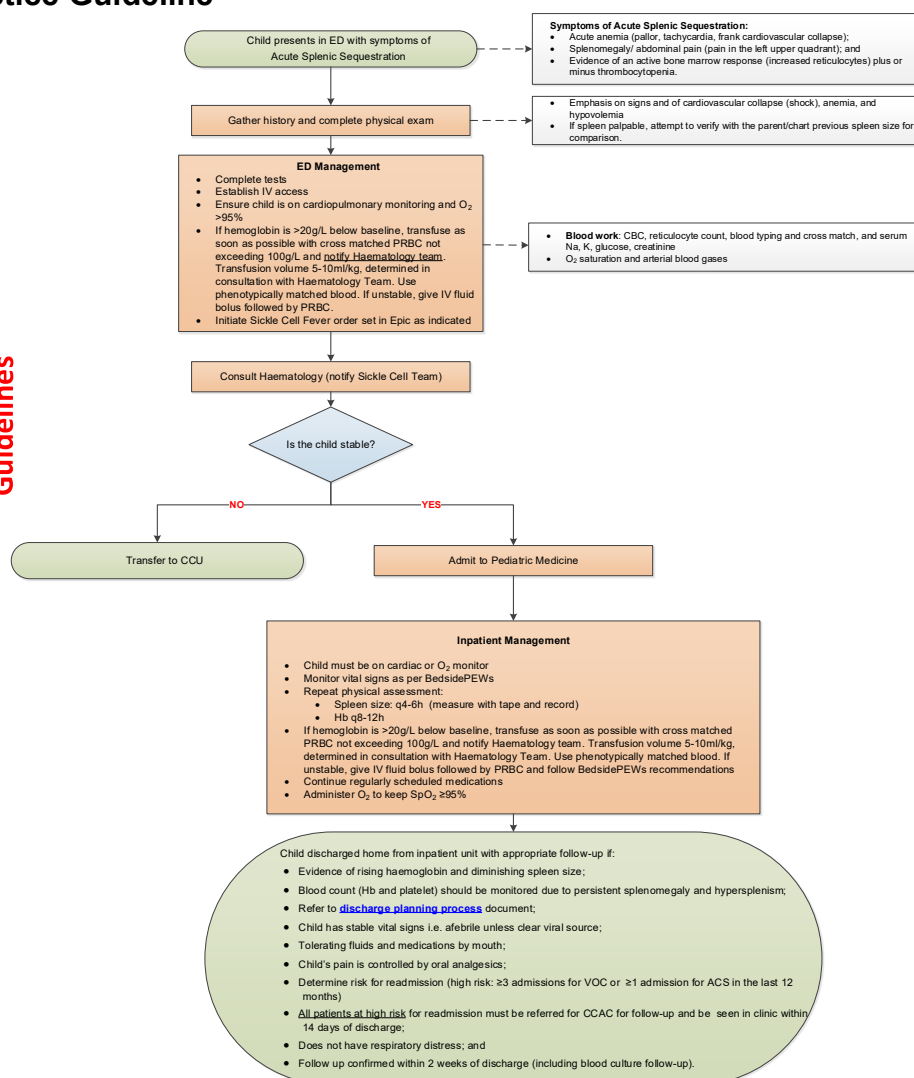
Retrospective reviews have shown a first-episode mortality of as high as 14%. On physical examination, patients show signs of anaemia, hypovolemia, and an enlarged spleen (larger than baseline), sometimes massively so. Mild cases may be asymptomatic.

Haemoglobin concentration is at least 20g/L below the baseline steady state. In severe cases, haemoglobin may decline to life-threatening levels. Reticulocyte counts are usually elevated, which distinguishes this condition from aplastic crisis. The platelet count often declines to $<50 \times 10^9/L$.

The mainstay of management is transfusion to provide circulating erythrocytes and volume. Risk of recurrence is approximately 40–50%, usually within 3 years. Because it is not possible to predict which children will have recurrent attacks, most experts recommend splenectomy after the first major attack (for patients >2 years old), or chronic transfusion to maintain a haemoglobin S level under 50% until the patient can get to surgery once all relevant immunizations have been completed.

3.0 Clinical Practice Guideline

Sickle Cell Anemia: Splenic Sequestration Management Guidelines



PRINTABLE VERSION

4.0 References

1. Emond AM, Collis F, Darvill D, et al. Acute splenic sequestration in homozygous sickle cell disease: natural history and management. *J Pediatr.* 1985;107(2):201–06.
2. National Heart, Lung, and Blood Institute. Evidence-based management of sickle cell disease: Expert panel report, 2014.

©The Hospital for Sick Children ("SickKids"). All Rights Reserved. This document was developed solely for use at SickKids. SickKids accepts no responsibility for use of this material by any person or organization not associated with SickKids. A printed copy of this document may not reflect the current, electronic version on the SickKids Intranet. Use of this document in any setting must be subject to the professional judgment of the user. No part of the document should be used for publication without prior written consent of SickKids.

3. Powell RW, Levine GL, Yang YM, et al. Acute splenic sequestration crisis in sickle cell disease: early detection and treatment. *J Pediatr Surg.* 1992;27(2):215–19.

Attachments:

[Revision History.docx](#)

[SC Clinic Follow Up Revised 2021_FINAL.pdf](#)

[Splenic Sequestration Care Pathway 2021 Final.pdf](#)